

Spontaneous Subarachnoid Hemorrhage Associated with the Use of Warfarin

Hemorragia Subaracnoide Espontânea Associada ao Uso de Warfarin

Linoel Curado Valsechi¹
Lucas Crociati Meguins¹
Dionei Freitas de Moraes¹
Antônio Ronaldo Spotti¹

ABSTRACT

Introduction: The most common cause of Subarachnoid Hemorrhage (SAH) is trauma and among spontaneous causes the rupture of intracranial aneurysms represents about 75 to 80%. The association between SAH and use of warfarin is a rare condition. **Case Report:** Female, 50 years, submitted to valvuloplasty surgery on May 2011, and in use of Warfarin since then, presented after one year with a severe headache, describing it as "the worst of her life", associated to paresis in the left side of the body. Admitted to the hospital in GCS 15 with neck stiffness due to hemiparesia in the left side and nasolabial sulcus shift to the right. The head CT (computed tomography) showed SAH Fisher II, without sign of ischemia. The international normalized ratio (INR) was 10. AngioCT did not show aneurism. The patient was taken to ICU, anticoagulant was suspended, the INR was corrected with fresh plasma, and K vitamin and neuroprotective measures were taken. After one month of hospitalization the patient had medical discharge in GCS 15, asymptomatic, with normalized INR and reintroduction of Warfarin. **Conclusion:** Intracranial hemorrhage associated to the use of oral anticoagulants is the leading cause of death in these patients. However, among them the isolated SAH is a rare event and therefore with few reports in the literature. The INR reversal therapy with the use of prothrombin concentrate, fresh frozen plasma and vitamin K have been adopted in the approach of these patients.

Key words: Subarachnoid Hemorrhage; Warfarin; International normalized ratio

RESUMO

Introdução: A causa mais comum de HSA é traumática e dentre as causas espontâneas, a ruptura de aneurismas intracerebrais representa cerca de 75 a 80%. A associação de HSA com o uso de Warfarin é uma condição rara. **Relato de caso:** Paciente feminino, 50 anos, submetida a cirurgia de valvuloplastia em março de 2011 em uso de Warfarina desde então, apresentou 1 ano após quadro de cefaléia de forte intensidade, descrita como a pior da vida, associado a fraqueza em hemisfério esquerdo. Admitida no hospital em Glasgow 15, com rigidez de nuca, hemiparesia em dimido esquerdo proporcionada e desvio de rima para direita. TC de crânio (tomografia computadorizada) evidenciou HSA Fisher II sem sinais de isquemia. International normalized ratio (INR) de 10. AngioTC não evidenciou formação aneurismática. Encaminhada para UTI, foi suspenso o anticoagulante oral, corrigido o INR com plasma fresco e vitamina K e realizadas medidas neuroprotetoras. Paciente teve alta um mês após admissão, em GCS 15, sem déficit motor, assintomática, com retorno da Warfarina e INR ajustado. **Conclusão:** As hemorragias intracranianas induzidas pelo uso de anticoagulante oral são a principal causa de morte nesses pacientes, porém dentre elas a HSA isolada é um evento raro e, portanto com poucos relatos na literatura. A terapia de reversão do INR com administração de concentrado de protrombina, plasma fresco e vitamina K tem sido adotada na abordagem desses pacientes.

Palavras-chaves: Hemorragia subaracnoide; Warfarin; International normalized ratio

INTRODUCTION

The most common cause of Subarachnoid Hemorrhage is trauma. Among the spontaneous causes of SAH, the rupture of intracranial aneurysms represents about 75 to 80%. Amongst other etiologies are arteriovenous malformations, dural sinus thrombosis, vasculitis, cerebral artery dissection and clotting disorders⁵.

Relationship between intracranial hemorrhage and the use of oral anticoagulants is well established by literature, mainly

intraparenchymal hemorrhages. However, SAH is a rare event in those cases, and in order to assign it to the use of anticoagulants it is necessary to exclude the existence of aneurysms or other vascular disorders by taking tests such as neuraxis MRI or cerebral angiography².

The objective of this article is to report an spontaneous SAH case associated to the use of warfarin and accomplish a short review about the subject.

¹ Division of Neurosurgery, Hospital de Base, Department of Neurologic Sciences, Faculdade de Medicina de São José do Rio Preto (FAMERP), São Paulo, Brazil.

CASE REPORT

Female, 50 years, hypertensive, submitted to valvuloplasty surgery on May, 2011 and since then in use of Warfarin, presented on May, 2012 with a severe headache, described as “the worst of her life”, associated to paresis in the left body. Admitted to the hospital in GCS 15, with neck stiffness, hemiparesia in the left side and nasolabial sulcus shift to the right.

The head CT (computed tomography) showed SAH Fisher II, without sign of ischemia. Laboratorial exams showed INR of 10. AngioCT did not show aneurysm. The patient was taken to ICU, and anticoagulant was suspended, the INR was corrected with fresh plasma and K vitamin and neuroprotective measures were taken. Arteriography also did not reveal aneurysm.

During hospitalization she presented a bilateral pulmonary embolism and cerebral salt-wasting, both properly corrected. After one month of hospitalization the patient was discharged in GCS 15, asymptomatic, with normalized INR and reintroduction of Warfarin.

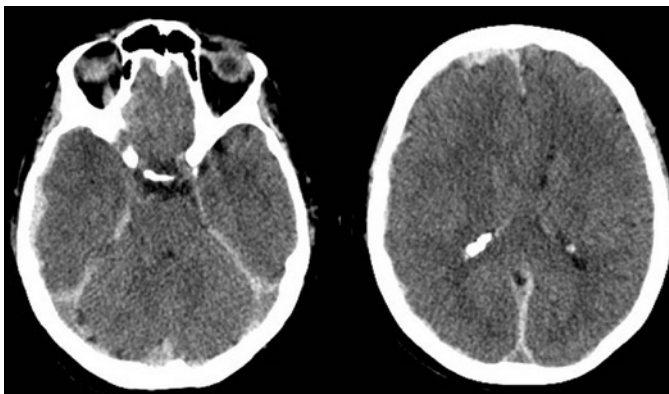


Figure 1. Brain CT showing SAH Fisher II

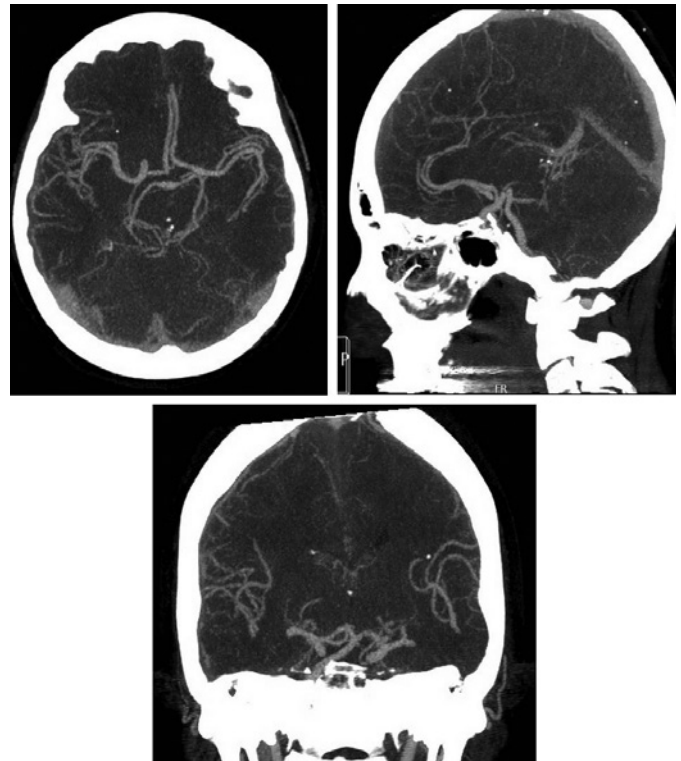


Figure 2. Brain AngioCT showing no evidence of aneurysms

DISCUSSION

Over 5-12% of intracranial bleeding are related to oral anticoagulants, the most lethal complication of their use. Intracranial bleeding can be divided into intraparenchymal, subdural / epidural and subarachnoid. Seventy percent of the cases are intraparenchymal, whose location in descending order of frequency is: in deep regions of the brain, cerebral hemispheres, cerebellum and brain stem. However, the relationship with SAH is a rare condition⁸.

Olsen et al. have shown that there is no increased risk of SAH associated with the use of oral anticoagulants⁷. On the other hand, more recent studies have suggested this association mainly with combined vitamin K antagonists, evidenced by Risselada et al. and Garcia-Rodriguez^{4,9}. Other authors have even pointed INR > 3.5 in patients under warfarin intake presenting intracranial haemorrhage, a two-fold risk of fatal event¹⁰.

The use of prothrombin complex concentrate associated with

fresh plasma and vitamin K also has shown good results in the literature as an approach for reversal of warfarin in cases of intracranial hemorrhage (ICH). However, as shown by Huttner, the time of reversal therapy does not seem to be related to increased bruising, being possible to occur after complete reversal of the INR with administration of frozen plasma and vitamin K. There was also no evidence of increased mortality or rebleeding in cases that restarted the use of warfarin after intracranial hemorrhage in high-risk group for thrombosis^{1,3,6,11}.

The initial volume of intracranial hemorrhage and its expansion, level of consciousness and site of bleeding are some of the factors related to the prognosis of the patient. In a multivariate analysis of mortality predictors were included INR > 3, intraventricular hemorrhage and massive SAH³. In another study, in addition to the volume of the ICH and the low level of consciousness, hyperglycemia was also considered as a factor of prognosis worsening because of the possible effect of swelling and hematoma enlargement in the area around the dead cells⁶.

CONCLUSION

Intracranial hemorrhage associated to use of oral anticoagulants are the leading cause of death in these patients, however among them the isolated SAH is a rare event and therefore with few reports in the literature. The INR reversal therapy with the use of prothrombin concentrate, fresh frozen plasma and vitamin K has been adopted in the approach of these patients, although there is no consensus in literature that the time of reversal therapy influences the increasing of bleeding or the prognosis of patients.

REFERENCES

1. Cabral KP, Fraser GL, Duprey J, Gibbons BA, Hayes T, Florman JE, Seder DB et al. Prothrombin complex concentrates to reverse warfarin-induced coagulopathy in patients with intracranial bleeding. *Clin Neurol Neurosurg*. 2013;115(6):770-774.
2. Campos RR, Cunha AM, Santos MES, Aguiar GB. Spontaneous Subarachnoid hemorrhage induced by warfarin Use: Case Report and Literature Review. *J Bras Neurocirurg*. 2011;22 (4): 190-193.
3. Claassen DO, Kazemi N, Zubkov AY, Wijdicks EF, Rabinstein AA.. Restarting anticoagulation therapy after warfarin associated intracerebral hemorrhage. *Arch Neurol*. 2008;65(10): 1313-1318.
4. García-Rodríguez LA, Gaist D, Morton J, Cookson C, González-Pérez A.. Antithrombotic drugs and risk of hemorrhagic stroke in the general population. *Neurology*. 2013 6;81(6):566-574.
5. Greenberg MS. *Handbook of neurosurgery*. 7th ed. New York: Thieme Medical Publishers, 2010. p. 1034.
6. Huttner HB, Schellinger PD, Hartmann M, Köhrmann M, Juettler E, Wikner J, et al. Hematoma growth and outcome in treated neurocritical care patients with intracerebral hemorrhage related to oral anticoagulant therapy: comparison of acute treatment strategies using vitamin K, fresh frozen plasma, and prothrombin complex concentrates. *Stroke*. 2006;37(6):1465-1470.
7. Olsen M, Johansen MB, Christensen S, Sørensen HT. Use of vitamin K antagonists and risk of subarachnoid hemorrhage: a population-based case-control study. *Eur J Intern Med*. 2010;21(4):297-300.
8. Ricarte IF, Calente FG, Alves MM, Gomes DL, Valiente RA, Carvalho FA et al. Cerebral Vasospasm and Delayed Cerebral Ischemia after Warfarin-Induced Subarachnoid hemorrhage. *J Stroke Cerebrovasc Dis*. 2015;24(9):e275-278.
9. Risselada R, Straatman H, van Kooten F, Dippel DW, van der Lugt A, Niessen WJ, et al. Platelet aggregation inhibitors, vitamin K antagonists and risk of subarachnoid hemorrhage. *J Thromb Haemost*. 2011;9(3):517-523.
10. Witt DM, Delate T, Hylek EM, Clark NP, Crowther MA, Dentali F, et al. Effect of warfarin on intracranial hemorrhage incidence and fatal outcomes. *Thromb Res*. 2013;132(6):770-775.
11. Yung D, Kapral MK, Asllani E, Fang J, Lee DS; Investigators of the Registry of the Canadian Stroke Network. Reinitiation of anticoagulation after warfarin-associated intracranial hemorrhage and mortality risk: the Best Practice for Reinitiating Anticoagulation Therapy After Intracranial Bleeding (BRAIN) study. *Can J Cardiol*. 2012;28(1):33-39.

CORRESPONDING AUTHOR

Linoel Curado Valsechi
Rua Lucas Mangini, 183/24 - Vila Santa Candida.
São José do Rio Preto, São Paulo, Brazil.
Zip code: 15091-270